

## My Prostate Cancer Story – Treating What You See – September 16, 2024 Update

### The Role of Early Detection and Focal Treatment Beginning with a Routine PSA Blood Test Followed by F-18 PSMA PET/CT, mpMRI, MRI Guided Biopsy, and Focal Hypo-fractionated Proton Therapy

On April 20, 2022, I received an elevated Prostate Specific Antigen (PSA) screening score of 5.97, which is slightly above the “Normal Level” of 4.5-5.5 for a man 70-80 years of age. Four previous scores since 2017 averaged 3.95, so the 5.97 score was elevated but the “standard of care” suggests that “active surveillance” would be the appropriate procedure. I waited six weeks to have the PSA test done again, and, on June 3, 2022, the score had been reduced to 4.70 which is well within the normal level for my age. I had no symptoms other than age related Benign Prostatic Hyperplasia (BPH), which is normal for men of my age. A PSA Fact Sheet from Cancer.Gov would suggest that I did not need to do anything further, and the risk factors were such that I didn’t really have anything about which to be concerned. See <https://www.cancer.gov/types/prostate/psa-fact-sheet> .

However, I was aware of a new F-18 PSMA PET/CT diagnostic procedure called PYLARIFY® (piflufolastat F 18). Pylarify is an “Injection of a radioactive diagnostic agent which is indicated for positron emission tomography (PET) of prostate-specific membrane antigen (PSMA) positive lesions in men with prostate cancer”. See <https://www.pylarify.com/> which states the following:

- PYLARIFY® PET/CT combines the accuracy of PET imaging, the precision of PSMA targeting, and the clarity of an 18F radioisotope.
- PYLARIFY® (piflufolastat F 18) injection is indicated for positron emission tomography (PET) of prostate-specific membrane antigen (PSMA) positive lesions in men with prostate cancer:
  - with suspected metastasis who are candidates for initial definitive therapy
  - with suspected recurrence based on elevated serum prostate-specific antigen (PSA) level
- NCCN Clinical Practice Guidelines in Oncology (NCCN Guidelines®) recommend piflufolastat F 18 Injection (PYLARIFY®) as an alternative to standard imaging of bone and soft tissue for:
  - Initial risk stratification for localized PCa (Prostate Cancer)
  - Detection of BCR disease after radical prostatectomy
  - Detection of BCR disease after radiation therapy
  - As workup for progression for evaluation of bone, pelvis, and abdomen
- NCCN Guidelines® for Prostate Cancer, V1.2022 further states: “Because of the increased sensitivity and specificity of PSMA-PET tracers for detecting micro-metastatic disease compared to conventional imaging (CT, MRI) at both initial staging and biochemical recurrence, the [NCCN] Panel does not feel that conventional imaging is a necessary prerequisite to PSMA-PET”.

In addition, Dr. Mark Scholz, Medical Oncologist and Medical Director of Prostate Oncology Specialists (see <https://www.prostateoncology.com/prostate-pros/mark-scholz-md/> ), states in his book, “The Key to Prostate Cancer”. “Younger men should consider doing a scan when the PSA is over 2.5; and if a man is older, a PSA over 4.0 should trigger further investigation with imaging”.

Based on the information on PSMA PYLARIFY® PET/CT and after discussions with a radiologist, medical oncologist, and radiation oncologist, I received a PSMA PYLARIFY® PET/CT referral and scheduled the procedure. The procedure was performed at the Provision Imaging Center in Knoxville, Tn on June 6, 2022 with the following conclusion:

*“Rounded 1 cm area of intense uptake involving the apex of the left prostate just to the left of midline. Although occasionally, retained excreted activity within the proximal urethra/prosthetic ventricle can mimic an abnormality in the region, however, I believe based on configuration and location (slightly left of midline) this is unlikely to be within the urethra and is quite suspicious for prostate carcinoma.*

*MRI of the prostate would be useful for further evaluation. No suspicious lymph nodes or evidence of distant disease."*

See Figure 1 below for the image of prostate cancer from the PSMA PYLARIFY® PET/CT procedure.

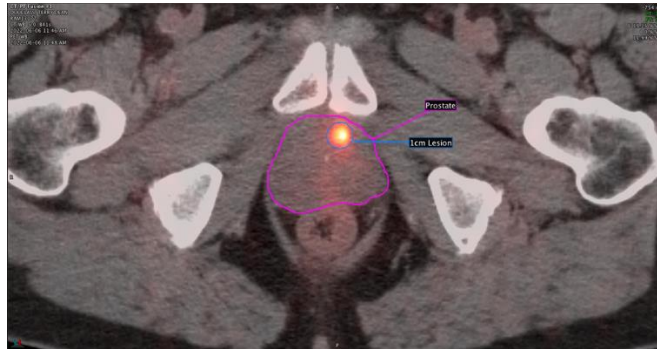


Figure 1 – Transaxial Image of PSMA PYLARIFY® PET/CT Showing 1 cm Rounded Lesion in Prostate

Note that there was no lymph node involvement or metastasis anywhere in the whole-body PSMA PET/CT study, which is critical to know what the treatment options might be and to the survival rate. Approximately 84% of prostate cancers are found when the disease is in only the prostate and nearby organs. This is referred to as the local or regional stage. The 5-year survival rate for most people with local or regional prostate cancer is greater than 99%.

A Multi-Parameter MRI (mpMRI) procedure was recommended and performed to confirm the diagnosis from the PSMA PET/CT procedure. Prior to the availability of PSMA PET/CT procedures, mpMRI was the accepted imaging procedure to confirm and localize prostate cancer prior to a needle biopsy.

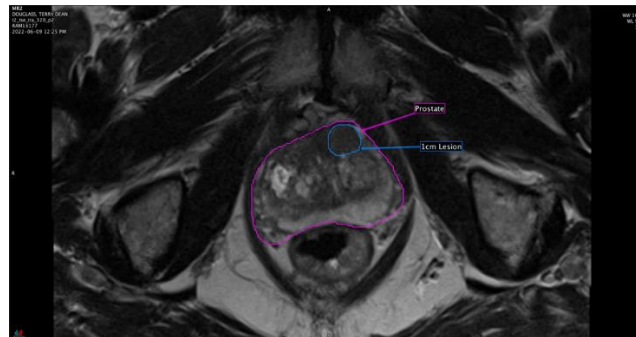


Figure 2 – Transaxial Image of mpMRI Showing 1 cm Rounded Lesion in Prostate

As one can see, the PET/CT PSMA images are distinct and definitive to prostate cancer. The mpMRI images, which are required for the biopsy, also show the lesion in the prostate but in a less defined image.

The next important question to answer after it is determined that there is cancer in the prostate is to determine if the cancer has spread to other parts of the body. For men diagnosed with prostate cancer that has spread to other parts of the body, the 5-year survival rate is 34%. Because the 5-year survival rate for men with prostate cancer that has spread is so poor, early detection is the most important factor in treating prostate cancer. About 1 man in 9 will be diagnosed with prostate cancer during his lifetime, and there is a 1 in 12 chance for men ages 70-79. In the USA, The American Cancer Society's

estimates for prostate cancer in the United States for 2024 are about 299,010 new cases of prostate cancer and about 35,250 deaths from prostate cancer.

The PET/CT images which were definitive for the radiologist’s suspicion of prostate cancer in the prostate also provide additional information from the whole-body PET/CT images as shown below.

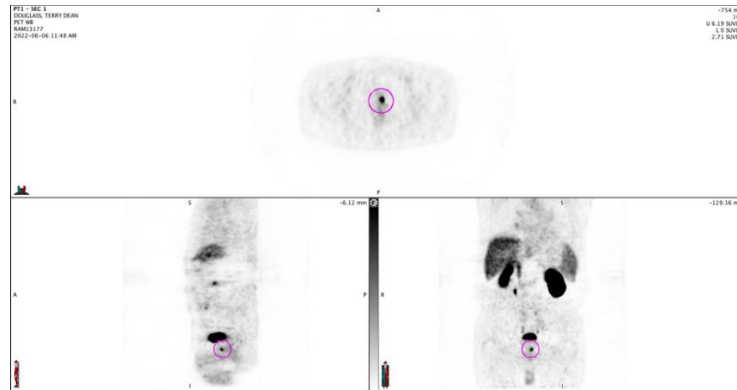


Figure 3 – F-18 PSMA PYLARIFY® PET/CT Pre-Treatment Trans-axial and Whole-Body Images

These above images showed no lymph node involvement and no metastasis. This additional information clarified that the cancer was localized as a 1 cm lesion in the prostate, and that there was no indication of prostate cancer anywhere else in the body. This additional information is what sets PSMA PET/CT imaging apart from any other imaging procedure for prostate cancer therapy management.

The next step in the process is a biopsy which is sent to the pathologist for the pathology report. I chose to have an MR guided (not MR assisted) biopsy because of the reduction in potential side effects due to the reduced number of tissue samples required for the MR guided method. My Pathology Report, dated June 14, 2022, is shown below and confirmed what the PSMA PET/CT found; and in addition, identified the prostate cancer as a “prostatic adenocarcinoma, Gleason pattern 3+4=7, Grade Group 2”.

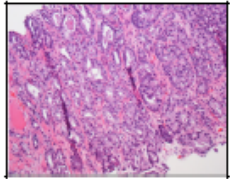
PATHOLOGY REPORT	
<p><b>DIAGNOSIS:</b></p> <p><b>1. Posterior Left Apex (MRI guided biopsy)</b>            Prostatic adenocarcinoma, Gleason pattern 3+4=7(30% pattern 4, Grade group 2)            15mm of tumor occupying 80% of tissue, 2 of 2 cores involved            Tumor present in skeletal muscle</p> <p><b>2. Anterior Right Apex (MRI guided biopsy)</b>            Benign prostatic tissue</p>	 <p>Cribriform 4</p>
ADDENDUM PATHOLOGY REPORT	
<p><b>ADDENDUM:</b>            Immunohistochemistry with appropriate controls was performed on block 1A for PTEN and ERG (TMPRSS2:ERG transformation product) in a section containing invasive carcinoma. The results are as follows:</p>	
<u>Results</u>	<u>Prognostic Group</u>
PTEN intact/No ERG overexpression	Favorable

Figure 4 – Pathology Report for Three-Sample MR Guided Biopsy of Localized Prostate Cancer

Additionally, the Addendum Pathology Report also showed favorable genetic results for prognosis for any future additional prostate cancer. This means that I did not need to have hormone therapy which has uncomfortable side effects.

The results of the PSMA PET/CT test and Pathology Report showed that my prostate cancer was focal and low grade which means that we could “treat what we could see”.

The choices for focal prostate cancer treatment that I considered included surgery, radiation therapy, TULSA (trans urethral ultrasound ablation) and proton therapy. I scheduled a consult for June 24, 2022 with Dr. Jim Gray, Medical Director of Provision CARES Proton Therapy Nashville and who is familiar with all prostate cancer treatments; and most importantly, he is familiar with F-18 PSMA and hypo-fractionated proton therapy. After our discussion concerning the risks of hypofractionation and focal treatment, Dr. Gray personalized my treatment to five-fraction focal proton therapy.

The process before starting my proton therapy treatment required a treatment planning CT, the placement of three gold fiducials in the prostate, and the insertion of a gel spacer to protect the bladder from excess radiation emanating from the focal treatment of the prostate cancer. This was done on a single day visit on July 1, 2022 to the Provision CARES Proton Therapy Center in Nashville and was painless with no side effects. The next step was the development of the treatment plan which was done at PCPT Nashville as well. Once the treatment plan was developed and approved by Dr. Gray, the schedule for the five treatments was split into two weeks with the first two treatments on Thursday and Friday, July 14-15, and the final three treatments on Monday, Tuesday, and Wednesday, July 18-20.



Figure 5 – Some of the Clinical Team Members at PCPT Nashville who treated me with great skill and showed me what the Provision Culture of CARE is really like.

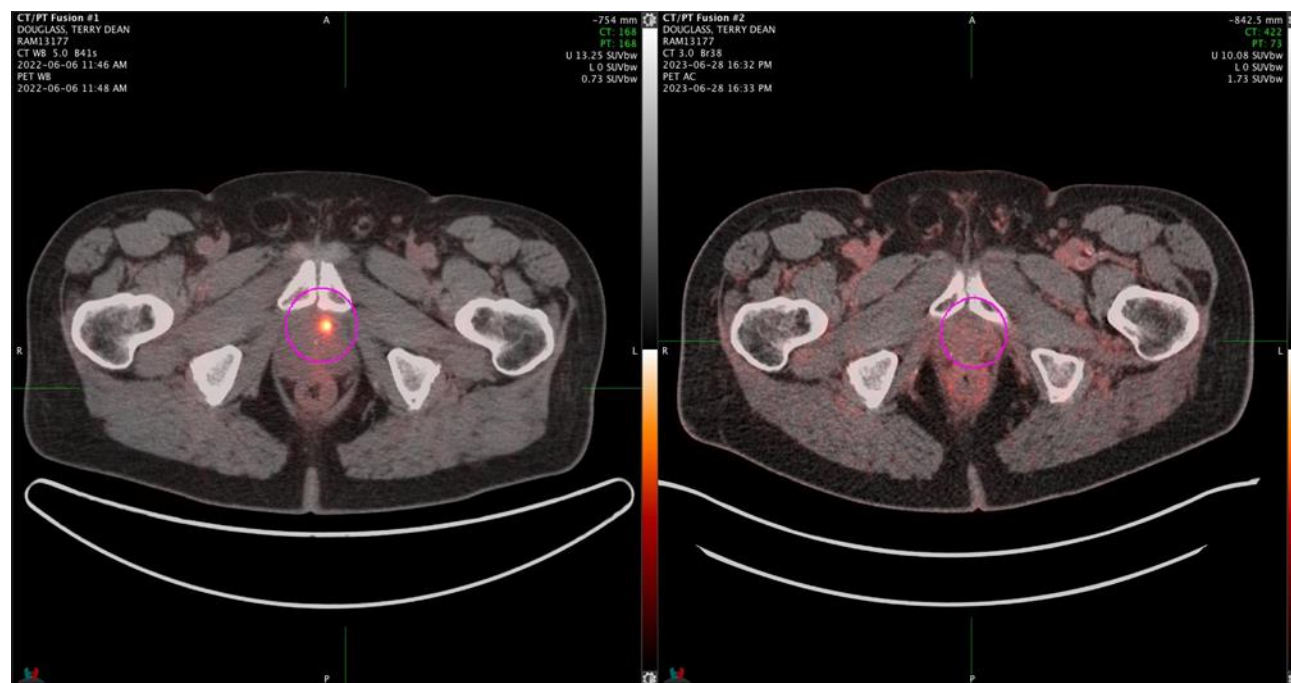
The whole process from the PSA to the PSMA PET/CT to the mpMRI to the MRI guided biopsy to the physician consult to the one-day prep to the five-day treatments did not interfere in any way with the rest



of what I would normally be doing and was painless and with no side effects. I did not miss a single day of my work or my daily walk averaging more than 12,000 steps per day over that period.

Since October 2022 when My Prostate Cancer Story was first written, I have continued to have no side effects from the proton therapy treatment and continue to live life as I did prior to the PSMA PET/CT diagnosis. I had a follow-up PSMA PET/CT scan on June 28, 2023 which showed that I was free of any indication of prostate cancer.

This follow-up PET/CT procedure was performed using a new F-18 PSMA PET/CT radiopharmaceutical called POSLUMA®. “POSLUMA® (flotufolastat F18) injection is indicated for positron emission tomography (PET) of prostate-specific membrane antigen (PSMA) positive lesions in men with prostate cancer”. The follow-up PSMA PET/CT images showed that I was free of any indication of prostate cancer in the prostate and continued to show no lymph node involvement and no metastasis as shown below. In addition, an unexpected added benefit was that my Benign Prostate Hyperplasia (BPH), which is common in men as they age, appeared to be improved based on a reduction in the size of the prostate in the follow-up PSMA PET/CT image.



Pre-Treatment PSMA PET

Post Treatment PSMA PET

Figure 6 - Comparison of Pre-Treatment F-18 PSMA PYLARIFY PET/CT with Post-Treatment F-18 PSMA POSLUMA PET/CT Images of Prostate Cancer

I have also had three Prostate Specific Antigen (PSA) scores since I was treated with all three showing that I was well within the normal range of 0 to 4.0 ng/ml. On January 09, 2023, 5 months after my proton therapy treatment, my PSA screening score was down to 1.07. On July 31, 2023, about one year after my proton therapy treatment, my PSA screening score was reduced even further to 0.47. The latest score was 0.53 on July 18, 2024. I will continue to have annual PSA tests to make sure that my prostate cancer does not need any additional treatment.

Some lessons that I learned that I would recommend to anyone suspicious of cancer.

1. **Learn as much as you can as soon as you can.** I recommend that you read the book referenced earlier by Dr. Mark Scholz, "The Key to Prostate Cancer" which can be ordered from Amazon. This book was published in 2018; so not much was known about PSMA PET/CT at that time. Dr. Scholz also has a series of YouTube videos on Prostate Cancer diagnosis and treatment. For a specific video on PSMA PET/CT, see <https://www.youtube.com/watch?v=CBILHS0FJfk>.
2. **Take control of your diagnostic and treatment process by learning as much as you can as quickly as you can.** I had a rising PSA blood test at my annual physical that went from 4.2 in August 2020 to 5.97 in April 2022 which was nothing about which to be too concerned. The normal procedure would be routine follow-up on the PSA blood test. However, I was aware of a new PET/CT diagnostic and therapy management test for prostate cancer (F-18 PYLARIFY® PET/CT) that had high specificity and sensitivity for prostate cancer, lymph node involvement, and proton therapy metastatic disease. So I chose to have this PSMA test done; and as a result, we found a 1-1.5 cm prostate cancer lesion on my prostate with no lymph node involvement and no metastatic disease.
3. **Do not be afraid to pursue possibilities that are not standard of care.** Not much of what I did would be considered "standard of care". Realizing that the prostate cancer was focused in a 1-1.5 cm. lesion from both the PET/CT PSMA test and the mpMRI test at the Provision Imaging Center, I chose MR guided biopsy with Dr. Joe Busch and The Busch Center in Atlanta. I also discussed transurethral ultrasound ablation with Dr. Busch which is a promising new treatment procedure that is a one-day outpatient treatment provided at The Busch Center.
4. **Search for physicians who are experienced in the diagnostic and therapy procedures that you are considering and who practice personalized precision advanced medicine.** Dr. Tracy Dobbs at Tennessee Cancer Specialists, Dr. Jud Gash at the Provision Imaging Center, Dr. Joe Busch at The Busch Center, and Dr. Jim Gray at the Provision CARES Proton Therapy Center in Nashville are the key physicians with whom I consulted in my diagnostic and treatment process.
5. **Do not hesitate to get a second opinion or search further if you don't feel comfortable with the information that you have received from your physician.**

Finally, if I can help in any way, please do not hesitate to contact me at [terry@pvhealthcare.com](mailto:terry@pvhealthcare.com).

Terry Douglass  
September 15, 2024

## Personal Note

Some have said that it is ironic or just “dumb luck” as my pastor friend facetiously said that I was personally and professionally involved in the following prostate cancer related diagnostic and treatment technologies and companies that contributed to my prostate cancer diagnosis and treatment:

- ORTEC, which developed the first PET system prototype in 1973 and the first commercial PET system in 1976,
- CTI Molecular Imaging, Inc., which was the commercial developer and manufacturer of the PET/CT system used to image the F-18 PSMA and which was founded in 1983 and merged with Siemens in 2005,
- PETNet, which manufactured the F-18 PSMA radiopharmaceutical that was used in the early detection of my prostate cancer, and which was merged with Siemens in 2005,
- Provision Diagnostic Imaging (PDI), which provided the PSMA PET/CT and mpMRI diagnostic procedures,
- ProNova Solutions, which manufactured the proton therapy system that was used to treat my prostate cancer, and
- Provision CARES Proton Therapy Nashville, which provided the proton therapy treatment.

Even though I was involved in each of the above-mentioned developments, my prostate cancer story was not about me; but all about God’s grace in providing opportunities that allowed me to be involved in these technologies and patient services. And providential care was the reason my prostate cancer was detected early by PET/CT imaging and treated successfully by focal proton therapy (“treating what you see”). I am blessed by and thankful for God’s Provision.

Terry Douglass  
September 15, 2024